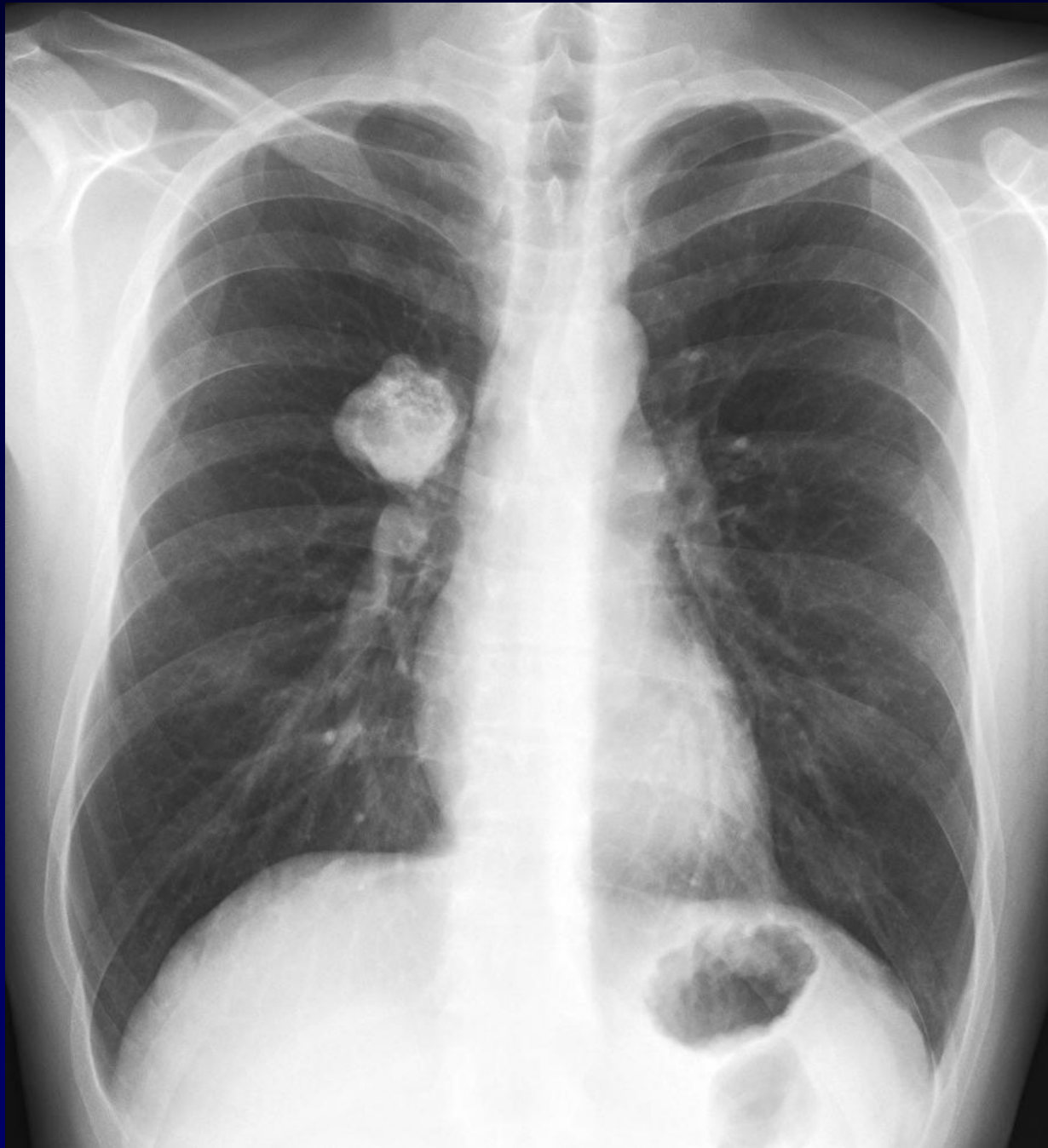

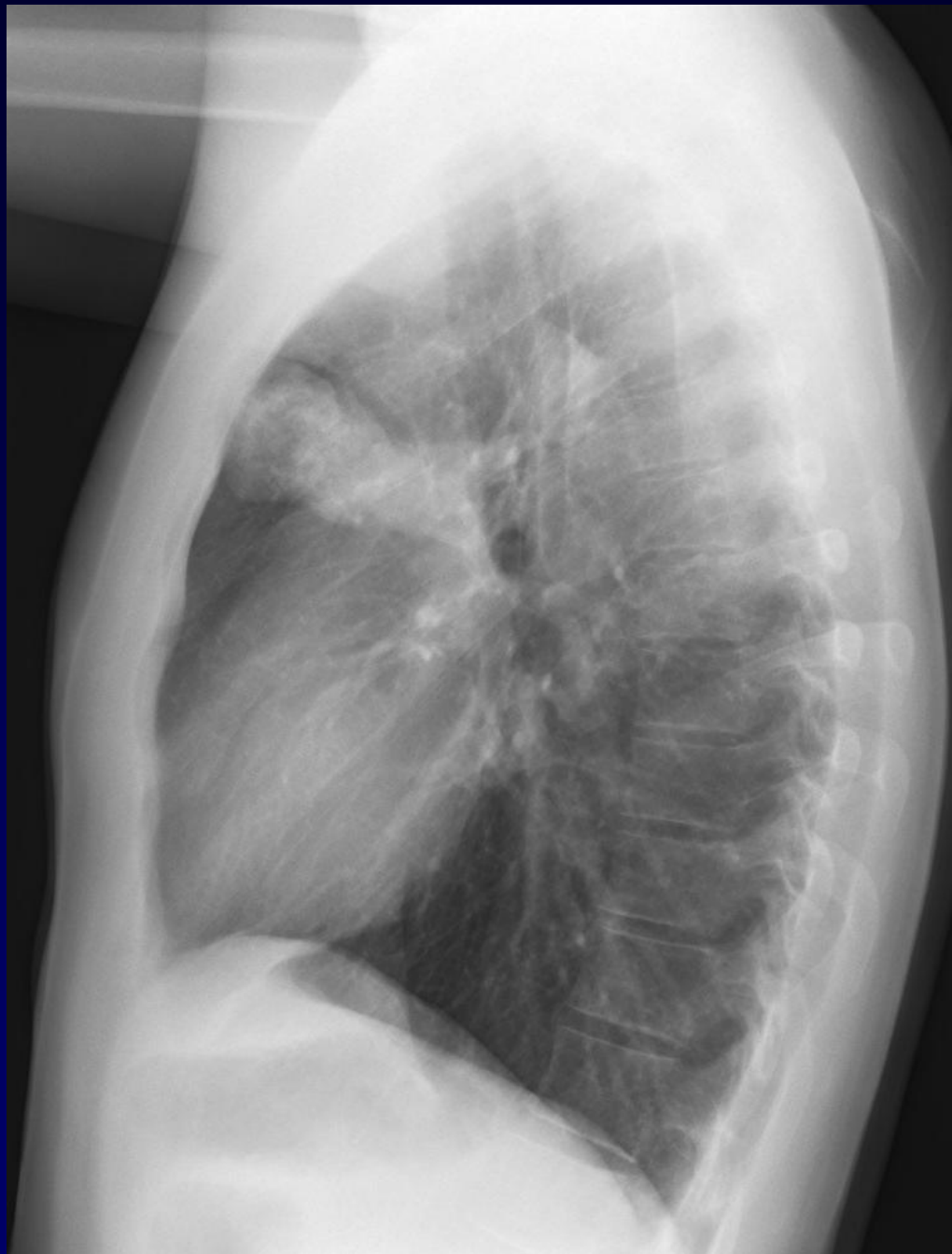


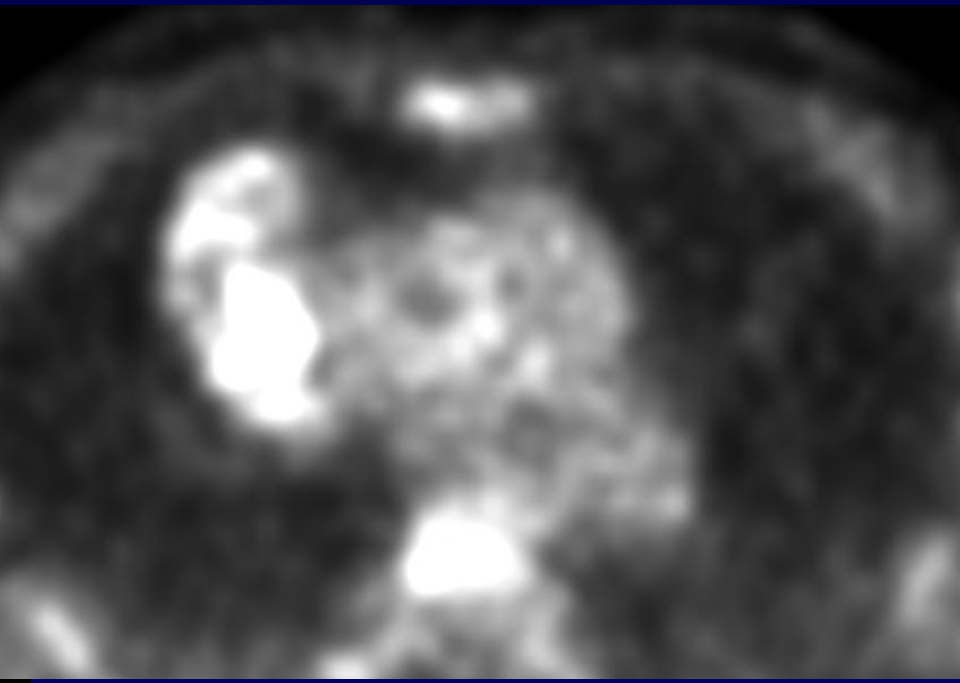
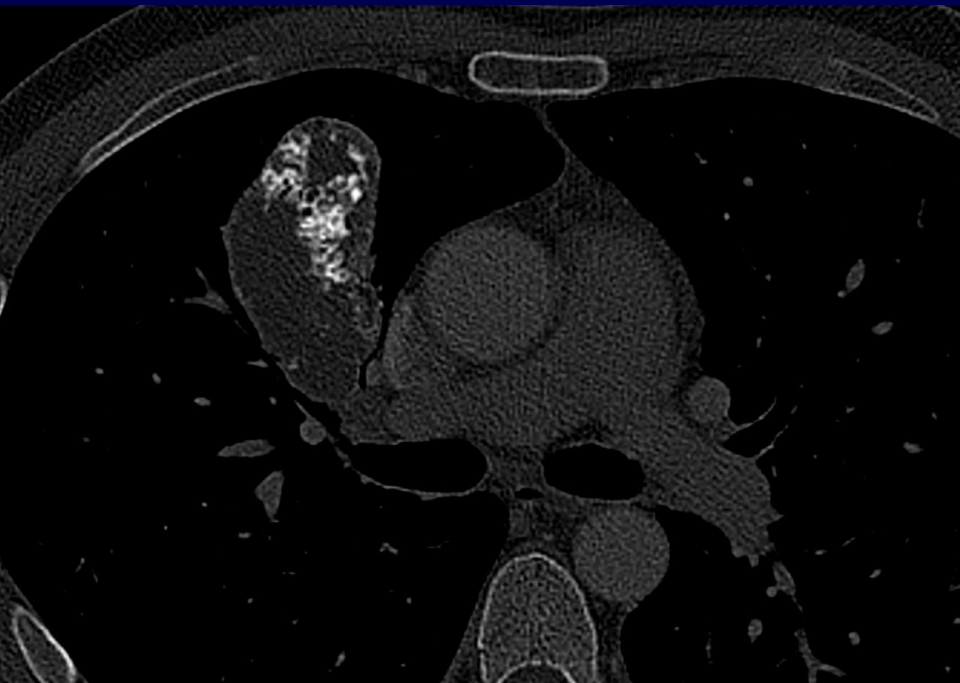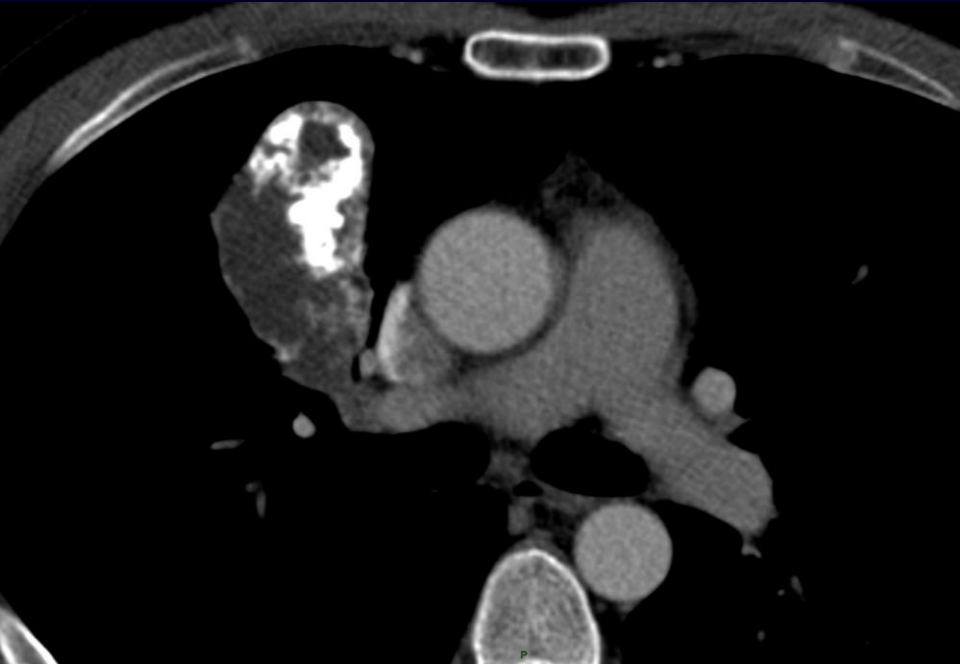
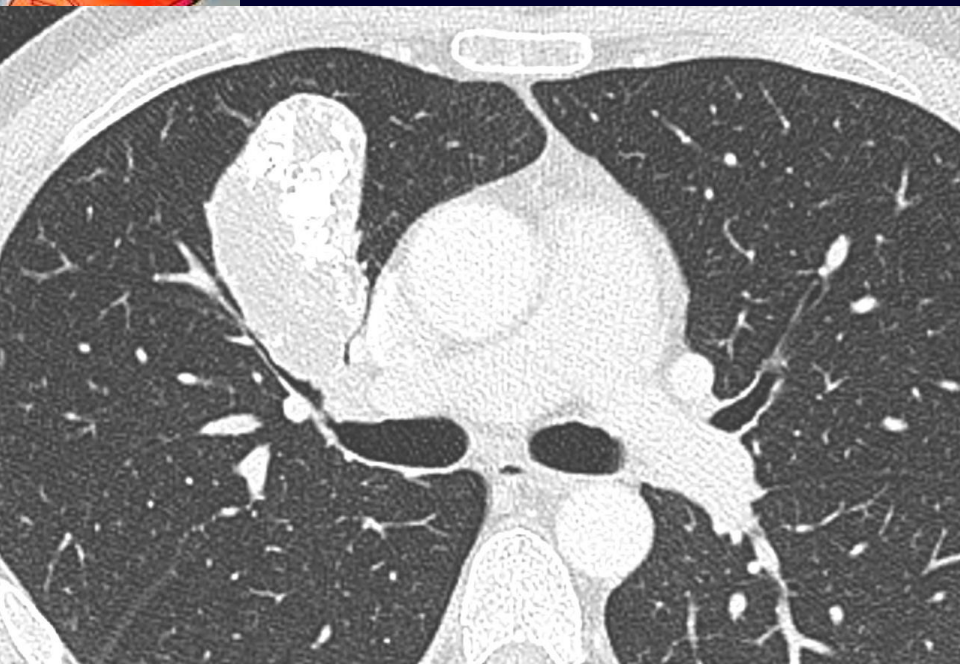MP Debray

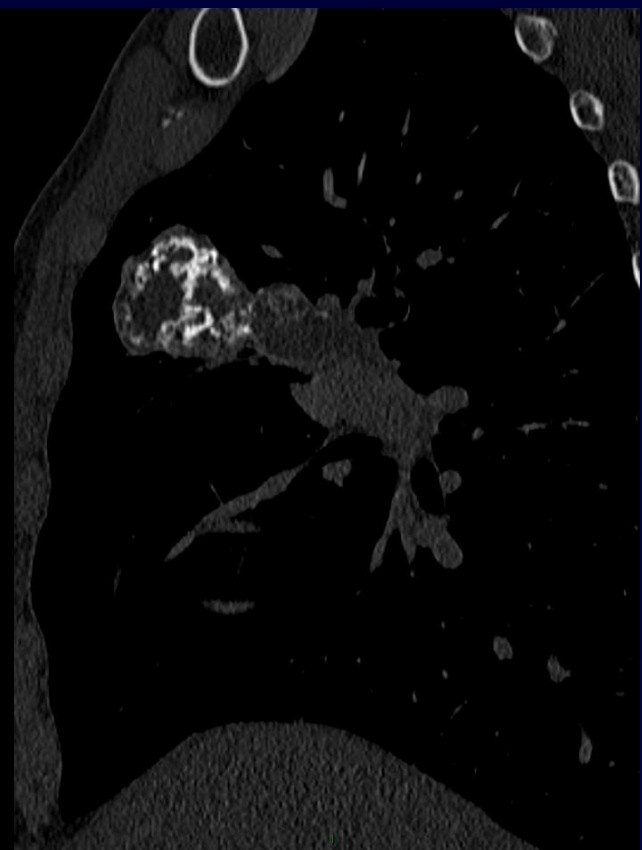
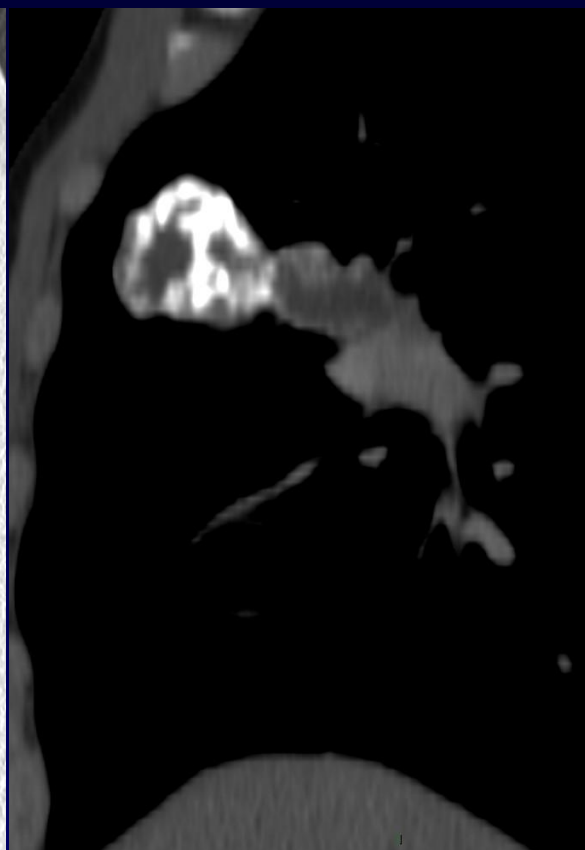
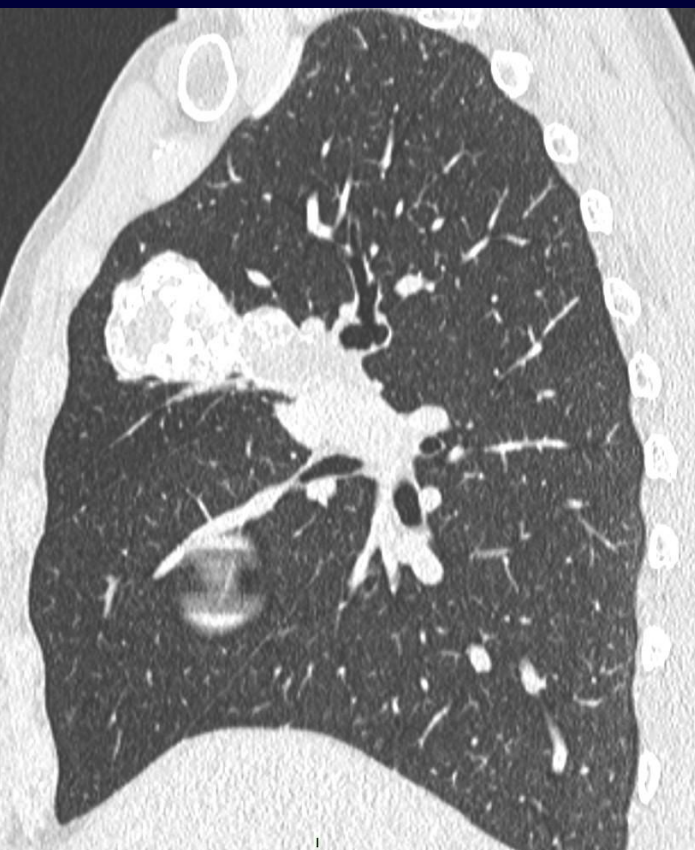
Homme de 37 ans

Radiographie systématique



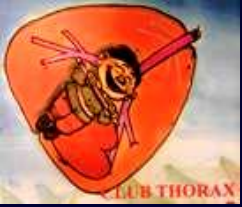







Diagnostic ?



Diagnostic

Chondrosarcome pulmonaire

- Hayashi T, Tsuda N, Iseki M, Kishikawa M, Shinozaki T, Hasumotofo. *Primary Chondrosarcoma of the Lung*. *Cancer* 1993;72:69-74.